

Chapter 5: Hand and Arm Abnormalities

Note: Color versions of all figures can be found in Supplemental Information on the FARF website (www.fanconi.org).

Introduction

Good to Know

Common terms in this chapter:

Hypoplasia. Underdevelopment or incomplete development of an organ or tissue in the body.

Pollicization. A surgical procedure that creates a functional thumb by moving the index finger and its nerves, arteries, tendons, and muscles to the thumb position.

Pouce flottant. A so-called “floating” thumb that lacks bones and is composed of skin and soft tissue.

Radius. The shorter and thicker of the two long bones in the forearm.

Radialization. A surgical procedure that realigns the patient’s wrist.

VACTERL Association. A group of birth anomalies that tend to occur together. See Table 1 for more information about these anomalies.

Approximately half of all children with Fanconi anemia (FA) have skeletal anomalies, most (~70%) of which affect the upper extremities. The most common abnormalities of the upper limbs involve the thumb and radius. Children with these anomalies might have a shortened or absent thumb, radius, or both, due to incomplete growth. Therapy or surgery may be required to maximize the function and appearance of the patient’s hands and arms.

This chapter will describe five common concerns related to the hand and arm in patients with FA:

- *An underdeveloped, missing, or duplicated thumb*
- *A shortened or missing radius*
- *A shortened, curved forearm*
- *A hand that develops perpendicularly to the forearm*
- *Impaired movement in the wrist, fingers, and elbow*

The hand and arm clinical care team should include a **hand and upper extremity surgeon** and, when needed, a **physical therapist** or occupational therapist. This team should work in close collaboration with other FA specialists to provide comprehensive care. The involvement of multiple types of care providers in the care of patients with FA introduces the risk that medications prescribed by one physician might adversely interact with those prescribed by another. Therefore, it is essential that all subspecialists communicate with the primary physician, usually the hematologist/oncologist, to coordinate care.

There are no standardized treatment procedures for congenital hand and arm abnormalities; treatments must be tailored to each child and family. The decision process is multi-factorial and requires participation from the family, physician team, and a physical or occupational therapist.

Initial Evaluation

Children born with limb abnormalities should be referred to an upper extremity specialist within the first few months of life. This physician should be comfortable with and proficient in the diagnosis and management of congenital limb anomalies. Ideally, a patient with FA should be referred to a hand and upper limb surgeon who specializes in pediatrics, because many physicians who care for limb problems in adults are not comfortable treating children.

The initial exam will lay the foundation for the relationship between the doctor, patient, and the patient's family. It will also provide parents with an opportunity to ask questions about the potential causes, treatments, and outcomes of their child's limb abnormalities. It is important for physicians to encourage this type of conversation; otherwise, parents often seek health information via the Internet, which can be a source of misinformation.

Many children with upper limb abnormalities require physical or occupational therapy, which may begin after the initial assessment. A physical therapist can help to stretch and strengthen the affected limb, and provide adaptive devices that maximize the patient's independence. As children get older and begin to perform increasingly complex physical activities, many parents will worry that their child's impairment is worsening, but in reality their child's activities may simply require additional strength and dexterity. A physical or occupational therapist can offer adaptive devices or techniques to help the child accomplish these tasks.

Limb evaluation often occurs before a patient is diagnosed with FA. Because the radius develops at the same time as many organ systems, the physician must evaluate the patient's entire body. Furthermore, radial deficiency—incomplete formation of the radius—is associated with numerous syndromes, further emphasizing the need for a thorough investigation (Table 1). Many children with VACTERL association have symptoms that are similar to those of children with FA, a diagnostic dilemma that can be solved with the chromosomal breakage test—the definitive clinical test for diagnosing FA. Some patients with VATER (or VACTERL-H) actually have FA, and a combination of radial and renal anomalies in VATER is an important clue in this diagnosis⁽¹⁾. The precise clinical indication for FA testing in children with limb anomalies is still evolving. Every child with isolated thumb or hand abnormalities should be tested for FA, and we recommend testing all children with deficiencies of the thumb and radius. Additional findings, such as skin discoloration (e.g., flat, light brown birthmarks known as café au lait spots), kidney abnormalities, growth retardation, and microcephaly (a small head), add to the suspicion of FA.

Table 1. Syndromes and other health conditions associated with radial deficiency.

Syndrome or Health Condition	Characteristics
Holt-Oram Syndrome	Heart defects, particularly defects of the cardiac septa (the tissues that separate the chambers of the heart)
Thrombocytopenia Absent Radius (TAR) Syndrome	Thrombocytopenia (platelet deficiency) present at birth May require blood transfusions, but improves over time Thumbs are present in TAR, but may be abnormal in shape
VACTERL Association (also discussed in Chapter 4)	<u>V</u> ertebral (spine) abnormalities <u>A</u> nal atresia (obstructed or improperly located anus) <u>C</u> ardiac (heart) abnormalities <u>T</u> racheoesophageal fistula (defects of the trachea (windpipe) and esophagus) <u>E</u> sophageal atresia (defects of the esophagus) <u>R</u> enal (kidney) defects <u>R</u> adial dysplasia (abnormal development of the radius on the thumb side of the forearm) <u>L</u> ower limb abnormalities
Fanconi anemia	Aplastic anemia that is not present at birth, but develops after about 6 years of life. (Aplastic anemia occurs when the body no longer produces enough blood cells.) If radii are absent in a patient with FA, thumbs are often absent as well.
CHARGE Syndrome	<u>C</u> oloboma of the eye <u>H</u> ear defects <u>A</u> tresia of the nasal choanae (blockage of one or both nostrils) <u>R</u> etardation of growth and/or development <u>G</u> enital and/or urinary abnormalities <u>E</u> ar abnormalities and deafness

Thumb Anomalies

In patients with FA, the thumbs may be underdeveloped or completely absent. The most common types of thumb anomalies that occur in children have been classified into five types depending on the degree of underdevelopment ⁽²⁾:

- **Type I deficiency.** In this type of deficiency, the child’s thumb is slightly smaller than normal but all of the thumb’s structures (including the bones, muscles, ligaments, tendons, and joints) are intact. This mild deficiency may go unrecognized, and many individuals with this type of deficiency are not diagnosed until later in life when everyday activities such as buttoning a shirt or tying shoes have become more difficult.
- **Type II deficiency.** This deficiency is more involved and is characterized by a narrowing of the web space between the thumb and index finger,

absence of the thenar (thumb) muscle at the base of the thumb, and instability of the metacarpophalangeal joint in the middle of the thumb (Figures 1A and B).



Figure 1A



Figure 1B

Figure 1. A 2-year-old child with type II thumb hypoplasia. *A)* Absent thenar muscles; *B)* Narrowed thumb-index web space with instability of the metacarpophalangeal joint. *Courtesy of Shriners Hospital for Children, Philadelphia Unit.*

- **Type III deficiency.** A child with this hypoplasia possesses the same characteristics as a Type II deficiency, as well as additional skeletal, muscular, and tendinous abnormalities. These abnormalities usually involve tendons that arise within the forearm and travel into the thumb. Type III anomalies are subdivided into types III-A and III-B depending upon the presence or absence of a stable carpometacarpal joint at the base of the thumb.
- **Type IV deficiency.** This type of deficiency, known as a pouce flottant (floating thumb) or residual digit, lacks bones and muscles and is mainly comprised of skin and soft tissue (Figure 2).

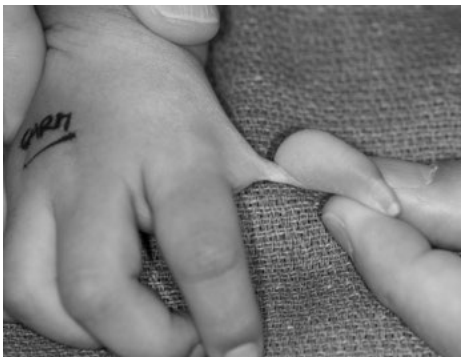

Figure 2 (see Figure legend on next page)

Figure 2. A 1-year-old child with severe type IV thumb hypoplasia (also known as a ‘pouce flottant’ or floating thumb). *Courtesy of Shriners Hospital for Children, Philadelphia Unit.*

- **Type V deficiency.** This type of hypoplasia is noted by the complete absence of a thumb (Figure 3).

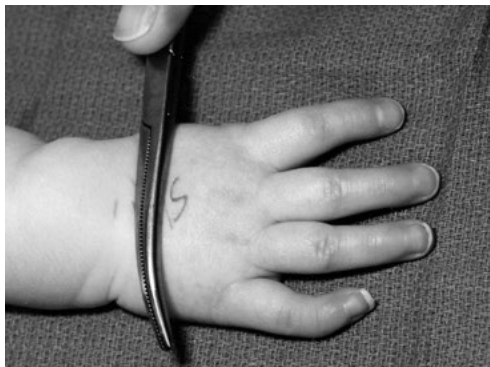

Figure 3

Figure 3. An 18-month-old child with type V hypoplasia and complete absence of the thumb. *Courtesy of Shriners Hospital for Children, Philadelphia Unit.*

The thumb classifications listed above can guide treatment recommendations, as shown in Table 2^(3,4,5). The degree of hypoplasia and deficiency varies among children with FA. As a result, treatment recommendations depend on the severity of the abnormality.

Table 2. Thumb deficiency classification and treatment paradigm.

Type	Findings	Treatment
I	Minor generalized hypoplasia	No treatment
II	Absence of intrinsic thenar muscles First web space narrowing Ulnar collateral ligament (UCL) insufficiency	Opponensplasty First web release UCL reconstruction
III	Similar findings as type II plus: Extrinsic muscle and tendon abnormalities Skeletal deficiency Stable carpometacarpal (CMC) joint (sub-Type III-A) Unstable CMC joint (sub-Type III-B)	Reconstruction (for sub-Type III-A) Pollicization (for sub-Type III-B)
IV	“Pouce flottant” or floating thumb	Pollicization
V	Absent thumb	Pollicization

Treatments for hypoplastic, floating, and absent thumbs

A thumb that is slightly smaller than normal (Types I, II, and III-A) can be reconstructed or stabilized by transferring tendon from another part of the hand to improve the thumb's motion and function. Type I deficiencies usually do not require surgical treatment, whereas multiple elements may need to be addressed in thumb reconstruction for Types II and III-A (Figure 4A thru C):

- **Tightness in the web space** can be released using skin flaps to increase the space between the thumb and index finger (Figure 4A).
- **Thenar muscle deficiency** can be treated by transferring tendon and/or muscle from the ring or long finger to the thumb. Tendon transfer improves the active motion and function of the thumb and has a negligible effect on the donor finger (Figure 4B).

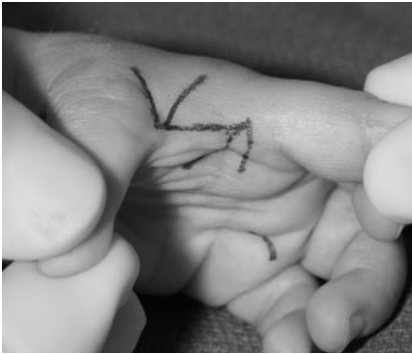

Figure 4A

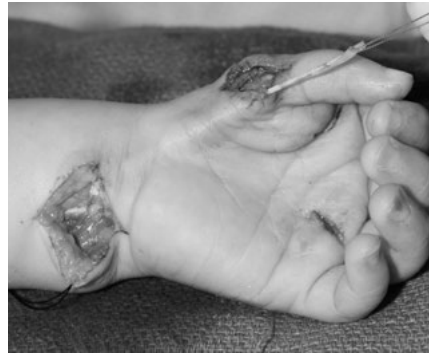

Figure 4B

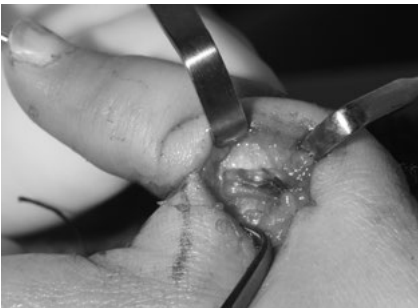


Figure 4C

Figure 4. Thumb reconstruction in Types II and III-A requires the surgeon to address all deficient elements. *A)* Z-plasty of the narrowed thumb-index web space; *B)* tendon transfer to overcome the deficient thenar muscles; *C)* ligament reconstruction to stabilize the metacarpophalangeal joint instability. *Courtesy of Shriners Hospital for Children, Philadelphia Unit.*

- **Metacarpophalangeal joint instability** can be improved through the use of grafts to the ulnar and/or radial collateral ligaments at the base of the thumb (Figure 4C). In cases with severe instability, fusion of the joint may be the best option to provide a stable thumb for firm grasps.

The main distinction between a thumb that can be surgically reconstructed and a thumb that requires amputation is the presence or absence of a stable base (e.g., a carpometacarpal joint). A thumb without a stable carpometacarpal joint (Types III-B, IV, and V) cannot be reconstructed and should be removed. Clinical examination and X-ray will show marked deficiencies (Figure 5 & 6). Furthermore, Type III-B and IV thumbs will not be functional and the child will not incorporate his/her thumb into pinch or grasp. The decision to remove a hypoplastic thumb without a stable base is often a difficult process for parents and caregivers. Discussions with the surgeon and conversations with families who have made similar decisions are often helpful to parents tasked with making this decision for their child (Video 1 in online supplementary information).

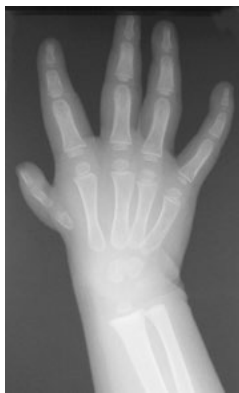

Figure 5

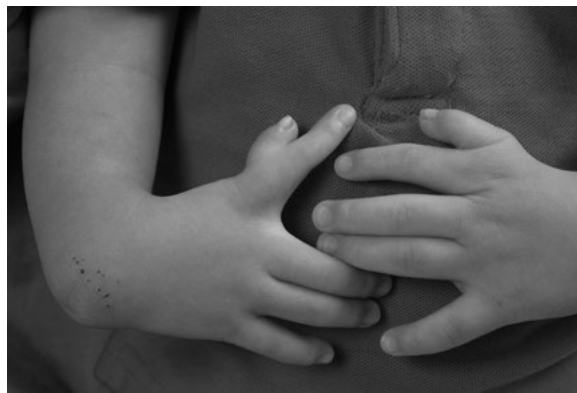

Figure 6

Figure 5. An X-ray of a 2-year-old child reveals a thumb metacarpal that tapers to a point, indicative of an unstable carpometacarpal joint. *Courtesy of Shriners Hospital for Children, Philadelphia Unit.*

Figure 6. A 5-year-old child with bilateral thumb hypoplasia. The right index-long web space has widened and the index has rotated out of the palm. *Courtesy of Shriners Hospital for Children, Philadelphia Unit.*

Because an opposable thumb is critical for manipulating many objects, a functional replacement can be constructed by surgically moving the index

finger and its nerves, arteries, tendons, and muscles to the thumb position. This procedure, known as pollicization, is generally performed when the child is between 6 months and 2 years of age, depending on the health status of the child, the degree of forearm deficiency, and the surgeon's preference^(2,3). This age range remains controversial, however, and there has been a trend toward surgery between 6 months to 1 year of age, which is prior to the normal development of oppositional or fine pinch at about 15 months of age. An intervention at an early age takes advantage of the growing brain's ability to adjust to the new thumb, and prevents the child from developing a compensatory side-to-side pinch pattern between adjacent fingers. The general medical health of a child with FA should also be taken into consideration prior to surgery, especially if the child's blood counts are decreasing over time. Surgery can be safely performed in patients who have platelet counts greater than 80,000. In reality, parents should not feel pressured to make an immediate decision about surgery for their child; some children undergo successful surgery during adolescence. Pollicization requires meticulous surgical technique because the index finger must be shortened, rotated, and reconstructed with the index muscles to give the appearance and function of a thumb (Figure 7). The surgeon should be experienced with this procedure.

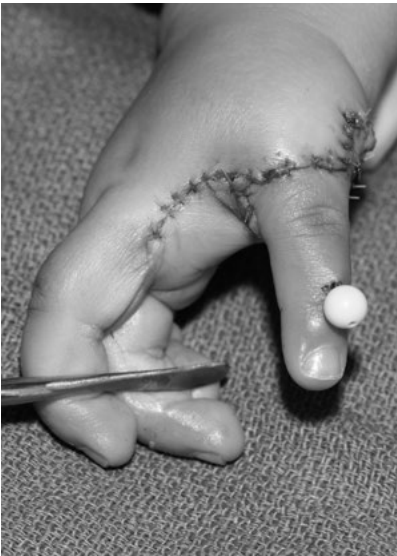

Figure 7

Figure 7. Pollicization of the index finger requires careful surgical technique to give the appearance and function of a thumb. *Courtesy of Shriners Hospital for Children, Philadelphia Unit.*

Distinguishing Between Type III-A and Type III-B Thumb Deficiencies

The clinical differentiation between Types III-A and III-B can be difficult. The child's pattern of thumb usage often helps discriminate between these types. An unstable thumb (Type III-B) will not be incorporated into pinching and grasping motions; rather, the child will learn to pinch and grasp using the index finger and the long digits, and the index finger will tend to rotate out of the palm toward a thumb position (Figure 5).

The differentiation is further complicated by the delayed maturation of the bones at the base of the thumb; these bones (the trapezium and trapezoid) do not finish developing until 4 to 6 years of age. Advanced imaging techniques such as magnetic resonance imaging (MRI) can reveal the extent of bone and cartilage development; however, young children require general anesthesia during MRI. Ultrasound imaging shows promise as a tool for defining the anatomy without the need for anesthesia.

A thumb metacarpal (the bone that connects the thumb to the wrist) that tapers to a point at the base of the metacarpal is also indicative of an unstable carpometaacarpal joint (Figure 6).

The outcome of pollicization is directly related to the status of the index finger prior to surgery: A mobile index finger can provide stability for grasp and mobility for fine pinch, whereas a stiff index finger will provide a stable thumb for coarse grasping, but fine pinching will be unlikely (Figure 8; Video 2 in online supplementary material). Good results shortly after pollicization have been shown to persist into adulthood ^(6,7).



Figure 8A
(see Figure legend on next page)



Figure 8B

Figure 8. A 2-year-old status post-pollicization of a mobile left index finger. *A)* Thumb used for grasping large objects; *B)* mobile thumb incorporated into fine pinch. *Courtesy of Shriners Hospital for Children, Philadelphia Unit.*

Other thumb anomalies

Although hypoplasia is the most common thumb anomaly in children with FA, other abnormalities have been reported. For example, the thumb can possess an extra bone (an anomaly referred to as a triphalangeal thumb) or can be duplicated (a condition called pre-axial polydactyly). The exact prevalence of these rare anomalies is unknown.

- ***A triphalangeal thumb*** has an extra bone (called a phalanx) that can vary in size and shape (Figure 9). The alignment and length of this type of thumb must be monitored until the bones have finished growing. An extra phalanx that is small and normally shaped can be treated without surgery; however, a small wedge-shaped phalanx may cause the thumb to curve away from its midline as it grows and treatment is recommended. A small wedge-shaped bone can be surgically removed and the ligaments of the remaining bones can be reconstructed to form a functional joint. A large wedge-shaped phalanx will cause the thumb to curve and become excessively long, but removal is not recommended because joint instability is common after surgery. A better option involves removing only the wedge-shaped portion of the abnormal phalanx and fusing the remainder to an adjacent thumb bone. This procedure eliminates the extra joint and shortens and realigns the thumb.

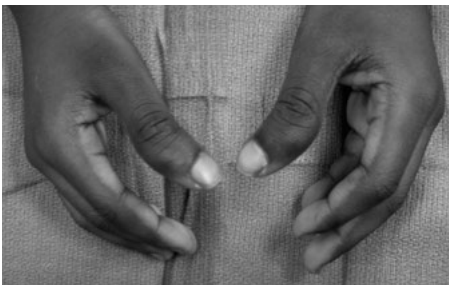

Figure 9A

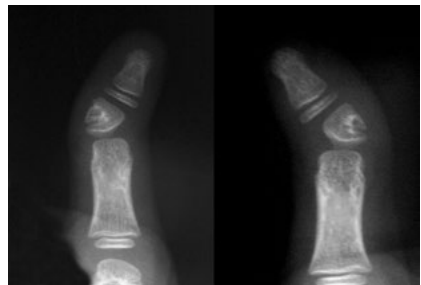

Figure 9B

Figure 9. An 8-year-old child with triphalangeal thumbs. *A)* Clinical appearance with mild angulation; *B)* X-rays show an extra phalanx that is triangular in shape causing the angulation. *Courtesy of Shriners Hospital for Children, Philadelphia Unit.*

- **Pre-axial polydactyly**, or duplication of the thumb, results in a hand that has more than one thumb. The thumbs may be partial and appear fused together, or they may be complete and separate from each other. Thumb duplications have been classified into various types depending on the degree of skeletal replication (Table 3)^(8,9). Treatment requires salvaging portions of each duplicated structure, including bones, nails, tendons, ligaments, joints, nerves, and blood vessels, to construct a properly aligned and functional thumb (Figure 10)⁽¹⁰⁾. This procedure is not always straightforward and requires careful examination. The soft tissues from the amputated thumb, including the skin, nail, ligaments, and muscle, should be used to augment the retained thumb. The articular surface of the joint may require realignment via osteotomy (cutting the bone) or modification through recontouring (cartilage shaving) to optimize thumb function. Irrespective of treatment, the reconstructed thumb may be smaller compared to a normal thumb and usually will lack some movement.

Table 3. Classification of duplicated thumbs⁽⁹⁾.

Type	Duplicated Elements
I	Bifid distal phalanx (a partial duplication of the bone at the tip of the thumb)
II	Duplicated distal phalanx (a complete duplication of the bone at the tip of the thumb)
III	Bifid proximal phalanx (a partial duplication of the bone in the middle of the thumb)
IV	Duplicated proximal phalanx* (a complete duplication of the bone in the middle of the thumb)
V	Bifid metacarpal phalanx (a partial duplication of the bone that connects the thumb to the wrist)
VI	Duplicated metacarpal phalanx (a complete duplication of the bone that connects the thumb to the wrist)
VII	Triphalangeal component (a thumb duplication with one or both of the thumbs having an extra phalanx or bone)

**Most common type of duplicated thumb.*

Modified from: Wassel HD. The results of surgery for polydactyly of the thumb: A review. In: 1969;125:175-193.

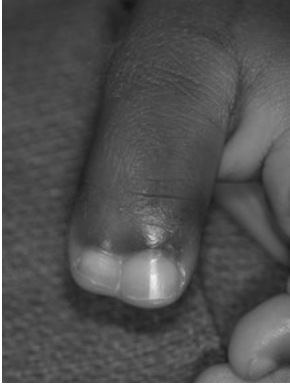

Figure 10A

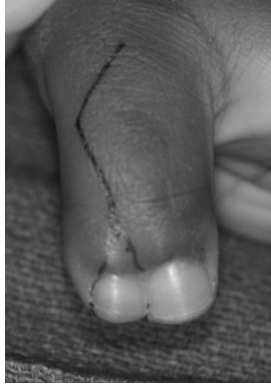

Figure 10B

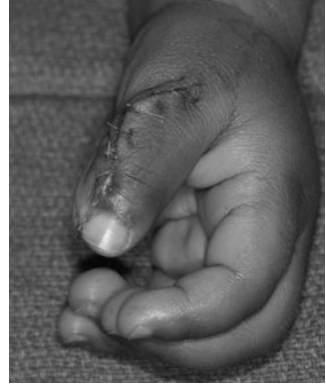

Figure 10C

Figure 10. A 1-year-old child with a duplicated left thumb. *A)* Clinical presentation; *B)* skin incision designed to incorporate parts of the deleted component; *C)* surgical reconstruction using the soft tissues from the deleted thumb to augment the size and girth of the retained thumb. *Courtesy of Shriners Hospital for Children, Philadelphia Unit.*

Radial Deficiency

Radial deficiency is a condition in which the radius—the bone that runs along the thumb side of the forearm—develops abnormally. The radius can be slightly smaller than average, considerably smaller, or altogether absent. The severity of radial deficiency is variable and can be determined through X-rays and clinical examination. Radial deficiency is classified as follows^(11,12):

- **Type 0 and 1 deficiencies.** These are the mildest forms and are characterized by little or no shortening of the radius and negligible curvature in the ulna. The hand may be tilted slightly inward toward the thumb side of the arm, a condition known as a radial deviation of the wrist, and substantial thumb hypoplasia may be present that requires treatment.
- **Type 2 deficiency.** This deficiency is characterized by a miniature radius that has abnormalities in the growth plate (the region of the bone responsible for lengthening the bone) and a moderate radial deviation of the wrist.
- **Type 3 deficiency.** This involves a partial absence of the radius—most commonly affecting the end of the bone that is closest to the wrist—and a severe radial deviation of the wrist.

- **Type 4 deficiency.** In the most common type of radial deficiency, characterized by a complete absence of the radius, the hand tends to develop perpendicularly to the forearm (Figure 11A and B). In children with FA, a complete absence of the radius typically occurs in conjunction with an absent thumb.

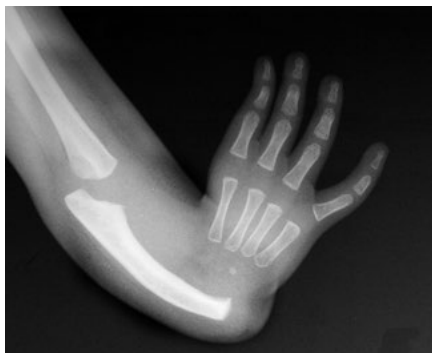


Figure 11A

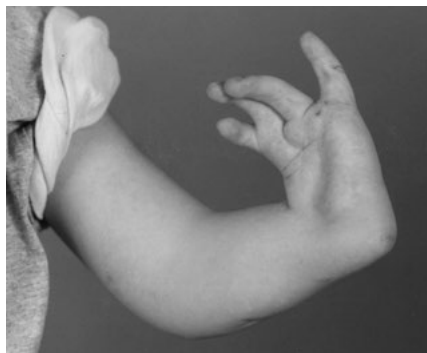

Figure 11B

Figure 11. A 2-year-old child with complete absence of the radius (Type 4). *A)* X-ray reveals complete absence of the radius; *B)* hand with a perpendicular relationship with the forearm. *Courtesy of Shriners Hospital for Children, Philadelphia Unit.*

The maturation of the radius takes more time than usual in patients with radial deficiency; therefore, the differentiation between total and partial absence (Types 3 and 4) cannot be determined until the child is approximately 3 years of age. The different types of radial deficiencies have been combined into a classification scheme that includes the other upper limb abnormalities that are associated with radial deficiency, including thumb, carpal (wrist), and forearm abnormalities (Table 4).

Table 4. Classification of radial longitudinal deficiency^(11, 12).

Type	Thumb	Carpus (wrist)	Distal radius (the end of the radius that is closest to the wrist)	Proximal radius (the end of the radius that is closest to the elbow)
N	Hypoplastic or absent	Normal	Normal	Normal
0	Hypoplastic or absent	Absence, hypoplasia, or coalition (fusion of two or more wrist bones)	Normal	Normal, radioulnar synostosis (an abnormal connection between the radius and ulna), or congenital dislocation of the radial head (a dislocated elbow)
1	Hypoplastic or absent	Absence, hypoplasia, or coalition	> 2 mm shorter than ulna	Normal, radioulnar synostosis, or congenital dislocation of the radial head
2	Hypoplastic or absent	Absence, hypoplasia, or coalition	Hypoplasia	Hypoplasia
3	Hypoplastic or absent	Absence, hypoplasia, or coalition	Physis (the bone region responsible for elongation of the bone) absent	Variable hypoplasia
4	Hypoplastic or absent	Absence, hypoplasia, or coalition	Absent	Absent

Modified from: Bayne LG, Klug MS. Long-term review of the surgical treatment of radial deficiencies. *J Hand Surg (Am)* 12:169-179, 1987; and Jame MA, McCarroll HR Jr, Manske PR. The spectrum of radial longitudinal deficiency: A modified classification. *J Hand Surg (Am)* 24:1145-1155, 1999.

Functional consequences of radial deficiency

The outcome of radial deficiency depends on the severity of the abnormality. In a patient with a Type 4 deficiency, the humerus (the bone between the elbow and shoulder) may be shorter than expected and the elbow may not be able to bend properly. Furthermore, the forearm will always be shortened because these children are born with an ulna that is approximately 60% of the normal length at birth and remains short even after the skeleton has completely matured⁽¹³⁾. The ulna will also be thickened and often curved toward the absent radius. In cases of partial or complete absence of the radius, the forearm will not be able to rotate, although some rotation may occur through the wrist or carpal bones. The wrist may be shifted a variable amount towards the deficient radius, a condition known as a radial deviation. The carpal bones

will be delayed in their growth, and the scaphoid and trapezium (two of the wrist bones) are often absent or reduced in size, or hypoplastic. The index and middle fingers can be stiff and slender and may have limited motion, whereas the ring and little fingers are less affected and often have better motion.

The radial artery and nerve are also often absent, although the ulnar nerve and artery are normal⁽¹³⁾. An enlarged median nerve substitutes for the absent radial nerve and communicates with its dorsal nerve branch, which is positioned in the fold between the wrist and forearm, to provide sensation to the thumb side of the hand. It is critical that surgeons are aware of the location of the dorsal branch when operating along the thumb side of the wrist.

Goals for treatment

The fundamental goals of treatment are to:

- *Correct the radial deviation of the wrist*
- *Balance the wrist on the forearm*
- *Maintain wrist and finger motion*
- *Promote growth of the forearm*
- *Possibly lengthen the forearm*
- *Improve the function of the arm*

Treatment considerations

A slightly shortened radius (Type 0 and 1 deficiency) requires repeated stretching and may need a tendon transfer to balance the wrist. These treatments are relatively straightforward. Partial or complete absence of the radius is more common (Types 2, 3, and 4) and is entirely more difficult to treat because the wrist has shifted toward the thumb side of the arm, shortening an already undersized forearm, placing the forearm flexor and extensor tendons at an awkward angle, and producing functional deficits. Children who have radial deficiency on only one arm (known as a unilateral deficiency) may be able to compensate for any functional deficits using their unaffected limb and thus have a lower overall degree of functional impairment than children who have radial deficiency on both arms (known as a bilateral deficiency). Finger and thumb abnormalities, if present, also require consideration during the formulation of a treatment plan, as stiff fingers and a deficient thumb will further hamper pinch and grasp.

Nonsurgical treatments

The treatment for radial deviation of the wrist begins shortly after birth and involves a combination of surgical and nonsurgical treatments. The initial treatment for an absent radius consists of stretching the soft tissues, including the tendons, ligaments, skin, and muscles. This treatment is typically performed both by a physical or occupational therapist and the caregiver. The therapist should be experienced in pediatric clinical interventions for the hand. Stretching should be performed at every diaper change and is an important part of the overall treatment plan. A splint can help to keep the hand in a straight alignment and prevent the hand from developing perpendicularly to the forearm; however, fabrication of a splint is difficult in a newborn with a shortened forearm because the splints tend to fall off the arm. Therefore, this treatment is usually postponed until the forearm is long enough to accommodate a splint. On occasion, the hand will develop in a perpendicular position despite treatment.

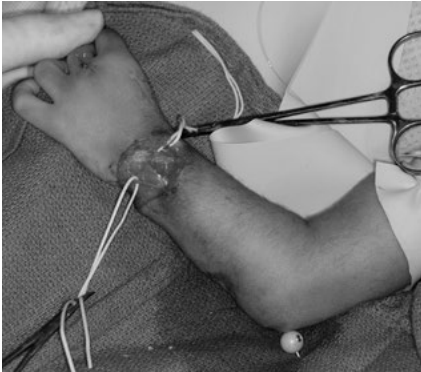

Figure 12

Figure 12. Surgical centralization requires placing the wrist on top of the ulna to realign the carpus onto the distal ulna. *Courtesy of Shriners Hospital for Children, Philadelphia Unit.*

Surgical treatment

Surgical treatment for Types 2, 3, and 4 deficiencies involves moving and centering the wrist over the end of the ulna, which is the only substantial bone remaining within the forearm. This procedure is known as “centralization” or “radialization” depending on the exact position in which the wrist is placed, and remains the standard treatment for realigning the wrist^(14,15). Centralization involves releasing and reorganizing the tight muscles and tendons of the wrist, and positioning the hand over the end of the ulna (Figure 12). One end

of a functioning tendon is then shifted from its original attachment site to the wrist to rebalance the forces acting on the wrist, a procedure known as tendon transfer. If the ulna has curved to an angle of 30 degrees or more, then it must be straightened via a procedure called concomitant wedge osteotomy at the time of surgery. Once the surgery is complete, the wrist is held in position by a stout wire (Figure 13), which can be removed 8 to 12 weeks after surgery, although some surgeons prefer to leave the wire in place for as long as possible. Once the wire has been removed, a splint should be used for 4 to 6 weeks. The splint can be removed for physical therapy exercises, but should be worn during sleep until the bones have completely matured.

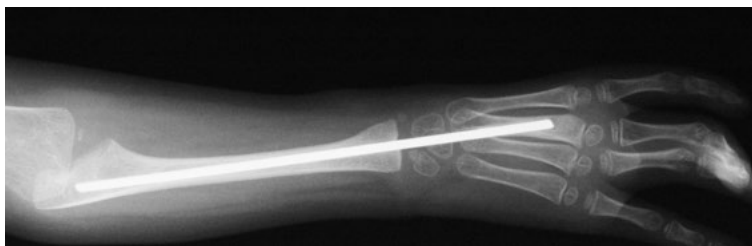

Figure 13

Figure 13. Centralization is maintained by placement of a stout wire across the wrist. *Courtesy of Shriners Hospital for Children, Philadelphia Unit.*

Centralization is typically performed when the child reaches approximately 1 year of age. The initial correction is often impressive; however, the results are unpredictable and, unfortunately, recurrence and complications are common. Furthermore, not all children are candidates for centralization. The caregiver and surgeon must remember that function trumps form, and many children function quite well despite having a deviated wrist. Such children typically have a mobile and dexterous little finger along with a stiff index finger, and are able to pinch and grasp using their palm and the fingers on the outside edge of the hand, known as an ulnar grasp pattern; straightening the child's wrist would move the outside edge and fingers downward and prevent the child from approaching objects with this side of the hand. Therefore, straightening may be detrimental to the child's overall function and independence.

Contraindications for surgery

Mild deformities with adequate support for the hand (Type 0 or 1) do not require surgery. Surgery is also not advised for children with impaired bending at the elbow. In these children, the radial deviation of the wrist enables the hand

to reach the mouth and straightening the wrist would impair important tasks such as eating and reaching the face.

Alternative treatments for recurrent radial deviation

In severe cases, the radial deviation cannot be straightened and alternative measures are necessary. Surgical options include removing a portion of the wrist bones via a procedure called carpectomy, shaving some of the bone off of the wrist end of the ulna, or applying a device called an external fixator prior to centralization. An external fixator stretches the soft tissues (including the tendons, ligaments, skin, and muscles) prior to centralization and facilitates correction of the radial deviation^(16, 17, 18). The fixator may be unilateral with pins or ringed multiplanar with wires (Figure 14).

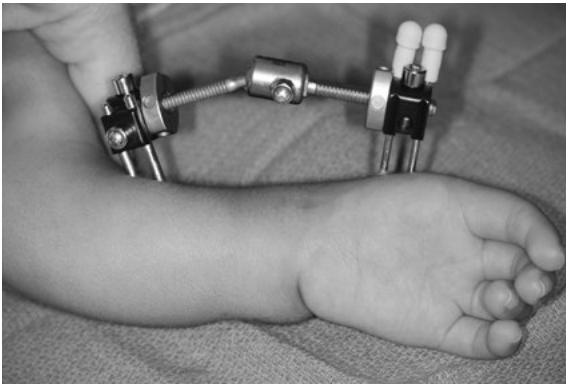

Figure 14A

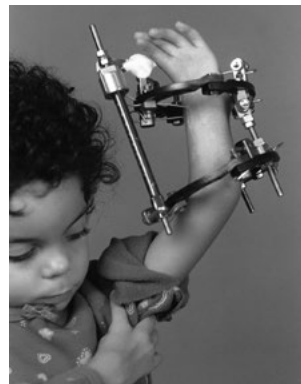

Figure 14B

Figure 14. Radial deficiency with rigid deformity is often treated with preliminary soft tissue distraction. *A)* Uniplanar device along the radial side of the forearm; *B)* multiplanar device for additional control of hand and forearm.

Courtesy of Shriners Hospital for Children, Philadelphia Unit.

Numerous other technical modifications have been proposed to maintain alignment of the wrist position. These include:

- **Overcorrection of the radial deviation.** In this procedure, the patient's hand is positioned slightly off-center into ulnar deviation to help prevent recurrence of the radial deviation.
- **Tendon transfers** to correct the alignment.
- **Prolonged wire fixation** following centralization (leaving the wire in place longer than the typical 8-12 weeks).

- **Microvascular free toe transfer**, which involves transplanting one of the second toes (without its skin but with its arteries and veins intact) to the thumb side of the wrist to provide additional support (Figure 15). A study of the outcomes of this procedure during an 8-year period revealed that patients tended to have improved wrist motion and limited recurrence⁽¹⁹⁾. This is a technically demanding operation, however, and complications are common.

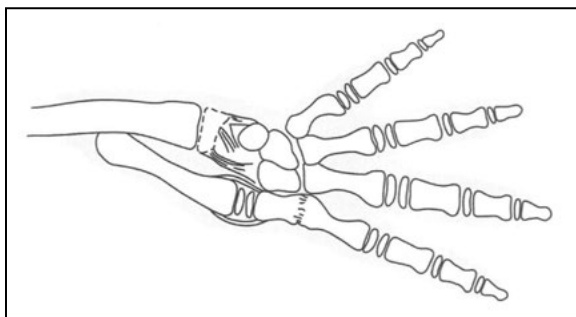


Figure 15

Figure 15. Diagram of free toe transfer to support the radial side of the wrist. The toe proximal phalanx is fused to the base of the second metacarpal and the proximal metatarsal affixed to the side of the distal ulna. Reprinted with permission from Kozin SH. Congenital Anomalies. Hand Surgery Update. Trumble TE, Budoff JE (eds), *American Society for Surgery of the Hand*, 2007, pp. 455-468.

Unfortunately, no treatment method consistently and permanently corrects the radial deviation, balances the wrist, and allows continued growth of the forearm^(14, 15). Recurrence can prove frustrating to the child, parent, and surgeon (Figure 16). Maintaining the wrist on the end of the ulna without sacrificing wrist mobility or stunting forearm growth remains a daunting task. Many factors contribute to recurrence, including the inability to obtain complete correction at surgery, inadequate release of the tightness in the soft tissues, and failure to balance the forces acting on the wrist. Prolonged wire fixation and use of a splint may help to prevent recurrence. In some children, there is a natural tendency for the shortened forearm and hand to deviate in a radial direction for hand-to-mouth use. Fortunately, recurrence is not always associated with a loss of function (Video 3 in online supplementary material). In fact, although patients with severe radial deviation may have limitations in their range of motion and strength, long-term studies have found that they have the same levels of activity and participation as children with less severe deformities^(20, 21, 22, 23).



Figure 16



Figure 17

Figure 16. An 11-year-old child with recurrent radial deviation following centralization as an infant. *Courtesy of Shriners Hospital for Children, Philadelphia Unit.*

Figure 17. Bilateral forearm lengthening using an external fixator. *Courtesy of Shriners Hospital for Children, Philadelphia Unit.*

The management of recurrent deformity must be individualized to each patient and his/her specific deformity. The indications for an additional procedure have yet to be clearly defined. Similarly, the indication for forearm lengthening to overcome the inherent problem of shortening has yet to be delineated. Lengthening surgery is offered to patients and families interested in correcting the deformity and willing to comply with a long and arduous recovery. The procedure, called distraction osteogenesis, involves inducing new bone growth, typically by pulling on the bone in a controlled manner using an external fixator (Figure 17). Lengthening is a sophisticated form of treatment that introduces additional complications such as infection at the insertion sites of the external fixator, fracture of the regenerated bone, and finger stiffness. These complications must be discussed prior to surgery. Forearm lengthening is laborious and may require the device to remain in place for extended periods of time, sometimes up to a year. In general, children with unilateral forearm shortening tend to be bothered by the asymmetry between the forearms and request lengthening more often than children with bilaterally shortened forearms, who have symmetry between the arms.

Ultimately, fusion of the joint between the wrist and ulna may be contemplated in certain instances to keep the wrist straight⁽²⁴⁾. Wrist fusion results in a permanently stiff, straight wrist. Careful assessment of hand usage and compensatory motion is mandatory prior to this procedure. A functional

evaluation by a therapist is a valuable preoperative tool. Painstaking measures should be taken to ensure that wrist fusion does not lead to loss of function.

Emotional Issues

Parents of children born with limb abnormalities are extremely concerned about the possibility that their child might experience peer pressure and taunting⁽²⁵⁾. The physician should acknowledge these concerns and encourage parental support. Literature is available to help children and families understand their child's limb anomalies, although discussions between clinicians and parents are the mainstay for improving understanding⁽²⁵⁾. School-age playmates are keenly aware of congenital limb differences and will be a source of questions and possible teasing. As congenitally different children grow, they develop inward and outward coping mechanisms to handle their anomalies. Support groups are invaluable, whether they are online or in person. The Internet, particularly social media, can be a valuable source of support for children and their families.

The physician should play an active role in the child's support system by encouraging open discussions about the limb differences and asking questions about the child's interactions with his or her peers. These conversations are often insightful and revealing to both the physician and family. Difficulties with peer pressure may require counseling to promote emotional development. Clinics that treat congenital hand abnormalities often have staff members with expertise in supporting the functional, emotional, and psychological needs of children and parents. Ideally, these staff members will include an occupational therapist, psychologist, and social worker. Children also benefit from peer-contact activities, such as summer camps for kids with upper extremity differences.

Transition from Childhood to Adulthood

By the time they reach adulthood, most children with FA have completed all necessary hand surgeries and will not require regular follow-up with their surgeon; however, occasional evaluation is recommended to check for any developing problems. Unfortunately, many pediatric facilities do not treat adults. Thus, patients should ask their pediatric hand surgeon to recommend a physician who cares for hand and upper extremity abnormalities in adults.

Chapter Committee

Roger Cornwall, MD, Scott H. Kozin, MD, and Ann Van Heest, MD*

**Committee Chair*

References

1. Alter BP, Rosenberg PS (2013) VACTERL-H association and Fanconi anemia. *Mol Syndromol* 4:87-93.
2. Lister G (1985) Reconstruction of the hypoplastic thumb. *Clin Ortho Rel Res* 195:52-65.
3. Kozin SH, Weiss AA, Weber JB, Betz RR, Clancy M, Steel H (1992) Index finger pollicization for congenital aplasia or hypoplasia of the thumb. *J Hand Surg* 17A:880-884.
4. Manske PR, McCarroll HR Jr, James MA (1995) Type III-A hypoplastic thumb. *J Hand Surg* 20A:246-253.
5. Graham TJ, Louis DS (1998) A comprehensive approach to surgical management of the type IIIA hypoplastic thumb. *J Hand Surg* 23A:3-13.
6. Clark DI, Chell J, Davis TR (1998) Pollicization of the index finger: A 27-year follow-up study. *J Bone Joint Surg* 80B:631-635.
7. Kozin SH (2012) Pollicization: The concept, technical details, and outcome. *Clin Ortho Surg* 4:18-35.
8. Cohen MS (1998) Thumb duplication. *Hand Clin* 14:17-27.
9. Wassel HD (1969) The results of surgery for polydactyly of the thumb. A review. *Clin Ortho Rel Res* 125:175-193.
10. Dobyns JH, Lipscomb PR, Cooney WP (1985) Management of thumb duplication. *Clin Ortho Rel Res* 195:26-44.
11. James MA, McCarroll HR, Manske PR (1999) The spectrum of radial longitudinal deficiency: a modified classification. *J Hand Surg* 24A:1145-1155.
12. Bayne LG, Klug MS (1987) Long-term review of the surgical treatment of radial deficiencies. *J Hand Surg* 12:169-179.
13. Heikel HV (1959) Aplasia and hypoplasia of the radius. Studies on 64 cases and on epiphyseal transplantation in rabbits with the imitated defect. *Acta Ortho Scand, Suppl* 39:1-155.
14. Bora FW Jr, Osterman AL, Kaneda RR, Esterhai J (1981) Radial club-hand deformity. Long-term follow-up. *J Bone Joint Surg* 63A:741-745.

15. Damore E, Kozin SH, Thoder JJ, Porter S (2000) The recurrence of deformity after surgical centralization for radial clubhand. *J Hand Surg* 25A:745-751.
16. Goldfarb CA, Murtha YM, Gordon JE, Manske PR (2006) Soft-tissue distraction with a ring external fixator before centralization for radial longitudinal deficiency. *J Hand Surg* 31:952-959.
17. Nanchahal J, Tonkin MA (1996) Pre-operative distraction lengthening for radial longitudinal deficiency. *J Hand Surg* 21B:103-107.
18. Taghinia AH, Al-Sheikh AA, Upton J (2007) Preoperative soft-tissue distraction for radial longitudinal deficiency: an analysis of indications and outcomes. *Plast Reconstruct Surg* 120:1305-1312.
19. Vilkki SK (1998) Distraction and microvascular epiphysis transfer for radial clubhand. *J Hand Surg* 23B:445-452.
20. Goldfarb CA, Klepps SJ, Daily LA, Manske PR (2002) Functional outcome after centralization for radius dysplasia. *J Hand Surg* 27A:118-124.
21. Holtslag I, Wijk IV, Hartog H, van der Molen AM, van der Sluis C (2013) Long-term functional outcome of patients with longitudinal radial deficiency: cross-sectional evaluation of function, activity, and participation. *Disabil Rehab*. 35:1401-1407.
22. Dana C, Aurégan JC, Salon A, Guéro S, Glorion C, Pannier S (2012) Recurrence of radial bowing after soft tissue distraction and subsequent radialization for radial longitudinal deficiency. *J Hand Surg Am*. 37:2082-2087.
23. Kotwal PP, Varshney MK, Soral A (2012) Comparison of surgical treatment and nonoperative management for radial longitudinal deficiency. *J Hand Surg Eur*. 37:161-169.
24. Pike JM, Manske PR, Steffen JA, Goldfarb CA (2010) Ulnocarpal epiphyseal arthrodesis for recurrent deformity after centralization for radial longitudinal deficiency. *J Hand Surg Am*. 35A:1755-1761.
25. Bradbury E (1998) Psychological issues for children and their parents. Buck-Gramcko D, ed. *Congenital Malformations of the Hand and Forearm*. London: Churchill Livingstone, pp. 48-56.